

# Pancreatitis Due to Hypercalcemia in a Young Adult

Mordechai Shimonov MD<sup>1,2</sup>, Lior Leibou MD<sup>1</sup>, Pinchas Shechter MD<sup>1,2</sup> and Arie Judich MD<sup>1,2</sup>

<sup>1</sup>Department of Surgery, Wolfson Medical Center, Holon, Israel

<sup>2</sup>Sackler Faculty of Medicine, Tel Aviv University, Ramat Aviv, Israel

**KEY WORDS:** acute pancreatitis, hypercalcemia, hyperparathyroidism

IMAJ 2012; 14: 267–268

**A**cute pancreatitis caused by hypercalcemia is a known but infrequent condition. Primary Hyperparathyroidism is the most common reason for hypercalcemia. This condition can occur at any age, but most cases occur in subjects over the age of 45 years [1], with female predominance of 2:1. We present a case of acute pancreatitis caused by hypercalcemia due to primary hyperparathyroidism in an 18 year old male.

## PATIENT DESCRIPTION

A previously healthy 18 year old male was admitted to our department with sudden-onset abdominal pain of 1 day duration. The pain was localized to the epigastrium and was associated with several episodes of vomiting and diarrhea. His past medi-

cal history was unremarkable. The patient was not taking any medications and had no history of drug or alcohol abuse.

On admission, vital signs were within normal limits, with body temperature of 36.8°C, heart rate 76 beats/minute, and blood pressure 140/86. Physical examination was notable only for mild tenderness in the upper abdomen. There were no palpable masses or peritoneal irritation. The rest of the physical examination was unremarkable.

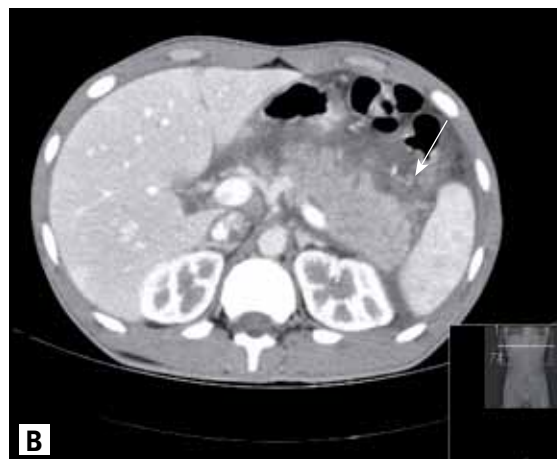
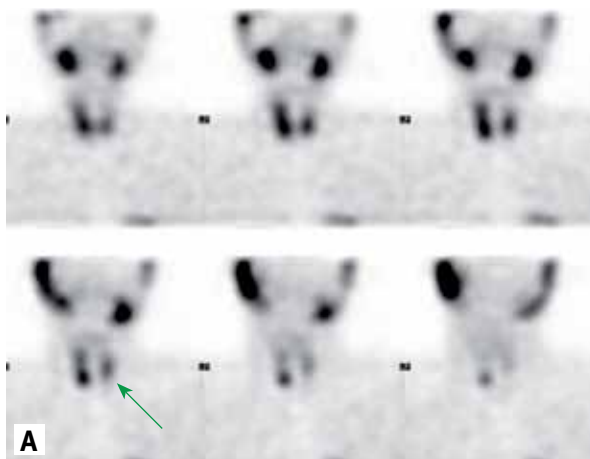
Laboratory tests revealed a high white blood cell count ( $19.4 \times 10^3/\mu\text{L}$ ), with normal hemoglobin (16.8 g/dl) and platelet counts ( $241 \times 10^3/\mu\text{L}$ ). Blood chemistry revealed a borderline glucose level (111 mg/dl), elevated amylase (1513 U/L) and lipase (2169 U/L), and high calcium (12.8 mg/dl) and low phosphorus (2.5 mg/dl) levels. Kidney and liver function tests, albumin and triglyceride levels were all within normal limits. Urinary samples were negative for illicit drug use.

The patient was treated initially with intravenous fluids and H2 blockers, and nothing per os. Abdominal sonography

later demonstrated a diffusely enlarged hypoechoic pancreas surrounded by free fluid. Cholelithiasis was not detected. Enhanced computed tomography demonstrated diffuse pancreatic enlargement and edema, ascites, and bilateral pleural effusion at the bases of the lung [Figure A].

Based on these clinical, radiographic and laboratory results, the diagnosis of acute pancreatitis was made and the etiology of hypercalcemia was suspected. Further evaluation confirmed the diagnosis of primary hyperparathyroidism, with elevated parathyroid levels (174 pg/ml, normal range 10–65 pg/ml), and normal 24 hour urinary calcium excretion (213 mg/24 hr, normal range 100–320 mg/24 hr). Ultrasound examination and SPECT scan with Tc-99m-sestamibi localized a solitary mass below the right lobe of the thyroid gland [Figure B].

Following his recovery from acute pancreatitis, the patient underwent an exploration of the neck that revealed a large mass (2 cm) behind the right lower lobe of the thyroid; the mass was removed. All other parathyroid nodes were identified



**[A]** Enhanced CT demonstrating diffuse pancreatic enlargement and edema

**[B]** SPECT scan with Tc-99m-sestamibi demonstrating a hot large zone at the right lower pole

as normal. The postoperative course was uneventful and the patient was discharged after 48 hours. His symptoms resolved and calcium and phosphorus levels returned to normal within 24 hours after surgery. Pathological examination of the excised mass confirmed the diagnosis of parathyroid adenoma weighing 0.9 g and measuring 2 x 1 x 0.5 cm. After a follow-up period of more than 3 months the patient was asymptomatic with normal calcium and phosphorus levels.

### COMMENT

Our patient represents an interesting example of acute pancreatitis caused by primary hyperparathyroidism. The incidence of acute pancreatitis secondary to PHPT is very low, with some variance. Bess et al. [2] reported an incidence of 1.5%, while others suggested higher rates (5.1%–12%) [3].

The clinical presentation of acute pancreatitis secondary to PHPT is not different from any other case of pancreatitis, and the diagnosis is based on clinical, laboratory and imaging studies. The diagnosis of PHPT is established by the presence of hypercalcemia (normal range 8.6–10.2 mg/dl) with elevated or normal serum PTH levels (normal range 10–65 pg/ml), as observed in our case.

The exact pathophysiological mechanism by which hypercalcemia causes pancreatitis is not fully understood, and may be associated with the combined effect of prolonged PTH secretion and hypercalcemia. One of the proposed

mechanisms is related to deposition of calcium in the pancreatic duct. These calcium ions activate trypsinogen within the pancreatic parenchyma, thereby inducing the damage. This theory is based on animal models of acute hypercalcemia that induced hyperamylasemia, intrapancreatic zymogen activation and histological changes of acute pancreatitis [4]. In addition, pancreatitis was reported in some patients receiving calcium infusions during cardiac surgery, in patients receiving total parenteral nutrition, and also in cases of vitamin D poisoning [4].

Parathyroid surgery is indicated in patients with symptomatic PHPT or in patients with asymptomatic PHPT who fulfill the 3rd International Workshop criteria for asymptomatic primary hyperparathyroidism [5]. These criteria include serum calcium concentration of  $\geq 1.0$  mg/dl above the upper limit of normal; creatinine clearance  $< 60$  ml/min; bone density at the hip, lumbar spine, or distal radius that is more than 2.5 standard deviations below peak bone mass (T score  $< -2.5$ ) and/or previous fragility fracture; and age less than 50 years. One or more of these criteria coupled with asymptomatic PHPT are an indication for surgery.

The best surgical approach for parathyroid surgery is still under debate. The classical method is bilateral neck exploration, which is suitable for most patients. Utilization of a minimally invasive approach became possible with new imaging methods enabling exact identification of the “diseased” parathyroid gland. The preoperative localization is achieved either with technetium-99m-sestamibi or ultrasound. These modalities allow the

surgeon to perform unilateral neck exploration directed at one parathyroid gland. The operative success is verified with intraoperative measurement of PTH levels or gamma probe confirmation of exact removal of the “hot” gland. Cessation of related symptoms is immediate (within the same hospital stay), as was demonstrated in our patient. Laboratory values were normalized within 24 hours after surgery in our case.

In conclusion, a high index of suspicion, together with a vigorous diagnostic workup, enhances the diagnosis of PHPT. Minimally invasive surgery following modern imaging technique carries an excellent prognosis.

### Corresponding author:

**Dr. L. Leibou**

Dept. of Surgery, Wolfson Medical Center, Holon 58100, Israel

**Phone:** (972-3) 502-8604

**Fax:** (972-3) 501-6601

**email:** liorleibou@hotmail.com

### References

1. Wermers RA, Khosla S, Atkinson EJ, et al. Incidence of primary hyperparathyroidism in Rochester, Minnesota, 1993-2001: an update on the changing epidemiology of the disease. *J Bone Miner Res* 2006; 21: 171-7.
2. Bess MA, Edis AJ, van Heerden JA. Hyperparathyroidism and pancreatitis: chance or causal association? *JAMA* 1980; 243 (3): 246-7.
3. Jacob JJ, John M, Thomas N, et al. Does hyperparathyroidism cause pancreatitis? A South Indian experience and a review of published work. *ANZ J Surg* 2006; 76: 740-4.
4. Khan AS, Latif SH, Eloubeidi MA, et al. Controversies in the etiologies of acute pancreatitis. *JOP J Pancreas* (Online) 2010; 11 (6): 545-52.
5. Bilezikian JP, Khan AA, Potts JT. Summary statement: guidelines for the management of asymptomatic primary hyperparathyroidism: summary statement from the Third International Workshop. *J Clin Endocrinol Metab* 2009; 94: 335-9.

### “Contempt is the weapon of the weak and a defense against one’s own despised and unwanted feelings”

Alice Miller (1923-2010), Polish-born French psychologist and world renowned author, who is noted for her books on child abuse by their own parents, translated into several languages

### “There is a foolish corner in the brain of the wisest man”

Aristotle (384-322 BCE), Greek philosopher and polymath, a student of Plato and teacher of Alexander the Great. Together with Plato and Socrates (Plato’s teacher), Aristotle is one of the most important founding figures in Western philosophy. His writings were the first to create a comprehensive system of Western philosophy, encompassing morality and aesthetics, logic and science, politics and metaphysics