

# Traumatic Cataracts in Children, Long-Term Follow-up in an Israeli Population: A Retrospective Study

Assaf Hilely MD<sup>1,3</sup>, Hana Leiba MD<sup>1,3</sup>, Asaf Achiron MD<sup>2,4</sup>, Idan Hecht MD<sup>4</sup> and Reut Parness-Yossifon MD<sup>1,3</sup>

<sup>1</sup>Department of Ophthalmology, Kaplan Medical Center, Rehovot, Israel

<sup>2</sup>Department of Ophthalmology, Wolfson Medical Center, Holon, Israel

<sup>3</sup>Hadassah-Hebrew University Medical School, Jerusalem, Israel

<sup>4</sup>Sackler Faculty of Medicine, Tel Aviv University, Tel Aviv, Israel

**ABSTRACT:** **Background:** Ocular trauma in the pediatric population may lead to cataract formation. Managing traumatic cataracts in a visually immature child is a major challenge and can result in poor visual outcome.

**Objectives:** To review our long-term surgical experience with childhood unilateral traumatic cataracts.

**Methods:** A retrospective observational study of children with unilateral traumatic cataracts with minimal follow-up of 5 years was conducted. Main outcomes included final visual acuity (VA) and occurrence of complications.

**Results:** Of the 18 children included in the study, 83% were male. Mean follow-up time was 12.5 years. Median age at injury was 7.5 years. Eleven patients (61%) presented with penetrating trauma injuries and 7 (39%) with blunt trauma. Sixteen patients (89%) had cataracts at presentation, while in two the cataracts developed during follow-up. Of the 18 total, cataract removal surgery was conducted in 16 (89%) with intraocular lens (IOL) implantation in 14 (87.5%), while 2 remained aphakic (12.5%). Two (11%) were treated conservatively. Long-term complications included IOL dislocation in 5 (36%), glaucoma in 7 (39%), and posterior capsular opacity in 10 (71%). No correlation was found between final visual acuity and the time interval between injury and IOL implantation nor between final VA and age at trauma. However, the final VA did correlate with time of follow-up.

**Conclusions:** Severe complications occurred in over 30% of the patients during a long follow-up (mean 12.5 years). This finding shows the importance of discussions between the operating physician and the parents regarding the prognosis and necessity of scheduled follow-up.

IMAJ 2019; 21: 599–602

**KEY WORDS:** blunt eye trauma, penetrating eye trauma, traumatic cataract, cataract surgery, children

Ocular trauma is a common cause of vision loss in the developed world, especially in the school-age pediatric population, and is a major etiology for unilateral cataract formation in a normal-sized eye [1]. Managing unilateral traumatic cataracts in a visually immature child is a major challenge and can result

in poor visual outcomes [2]. Until the early 1980s, patients with traumatic cataracts were left aphakic and wore contact lenses to correct the resulting refraction error [3]. The development of new microsurgical techniques with biocompatible materials and better intraocular lens (IOL) designs allowed for IOL implantation in children. Early IOL implantation is now universally recommended for pediatric traumatic cataract patients older than 2 years of age [4]. Reported postoperative results generally show good visual outcome with up to 35% of patients achieving visual acuity of 20/40 [5]. However, the reported follow-up periods of pediatric traumatic cataract have varied in length with a limited number of studies reporting over 10 years of follow-up Figure 1 and Table 1 (online version only). In Israel, results of IOL implantation in children with traumatic cataract have been reported by Blumenthal et al. in 1983 [6], Hemo et al. in 1987 [7], BenEzra et al. in 1997 [8], Moisseiev et al. in 2001 [9], and Leiba et al. in 2006 [10].

The aim of this study was to describe the updated long-term final visual outcome and complications among Israeli children treated for unilateral traumatic cataracts in our hospital, for a longer follow-up period.

## PATIENTS AND METHODS

This retrospective observational study was approved by hospital administrators and the institutional ethics committee in agreement with the Helsinki Declaration.

We included patients who were younger than 18 years of age, diagnosed with unilateral traumatic cataracts, and subsequently treated at our pediatric ophthalmic practice between January 1983 and December 2012, including a minimum follow-up period of 5 years.

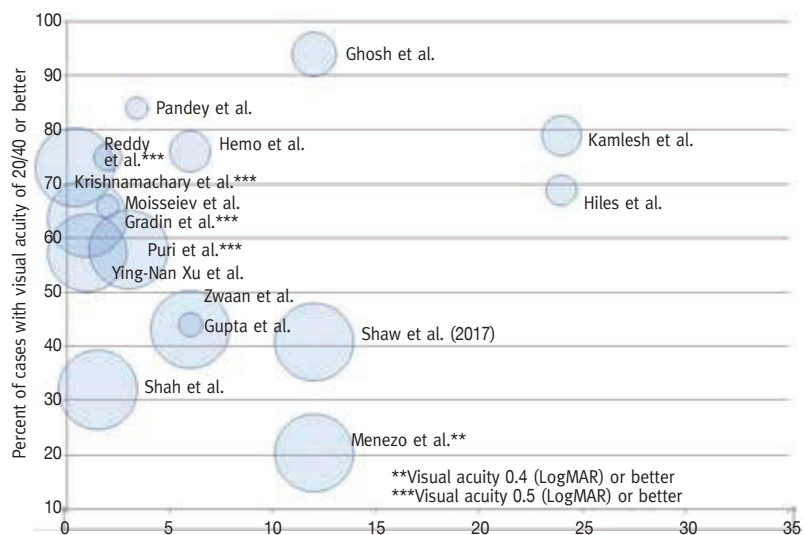
We excluded patients with posterior segment involvement or a follow-up period of less than 5 years. Each patient's medical records were reviewed for demographic information such as age and gender, associated ophthalmic history, detailed data on the mode of injury, and visual acuity. All children had unremarkable medical and surgical histories before their injuries.

On first admission visual acuity was obtained, and when possible, slit lamp and fundus examinations were performed.

**Figure 1.** Summary of studies on pediatric traumatic cataracts

The X axis represents follow-up in years, the Y axis represents percentage of patients with visual acuity of 20/40 or better. Circle sizes represent the number of patients in each study. For example, the study by Pandey et al. had a relatively small number of patients ( $n=20$ ), follow-up was relatively short (~3 years), and approximately 85% of patients had visual acuity or 20/40 better. Size indicates the number of patients. For clarity purposes cohort of over 70 are sized equally. The general trend was seen for deterioration in visual acuity with longer follow-up, a trend which was also seen in our results as final visual acuity was negatively correlated with follow-up time ( $r = 0.51$ ,  $P = 0.03$ )

References are available in the online supplemental reference list [1–21]



In cases involving an opaque media, the posterior segment was evaluated by B-scan ultrasound. The surgical technique was chosen according to cataract type and the morphology of the tissues surrounding the lens. Patients with traumatic cataracts had cataract surgery, with or without IOL implantation, either in conjunction with the perforation repair or as a secondary procedure after the intraocular inflammation had subsided. The patients were divided into two main groups: penetrating trauma and blunt trauma. They were further divided into whether an IOL was implanted and then according to complications, final visual acuity, and the time interval between original injury and lens implantation. Postoperatively, all children were treated with a topical instillation of dexamethasone, ofloxacin, and cyclopentolate. Visual acuity was measured by Snellen visual acuity, Teller acuity cards, or by observing ocular motor fixation patterns in patients too young to respond to subjective visual testing. Finally, an evaluation of intraocular pressure and detailed slit lamp biomicroscopy were performed. Part-time, daily occlusion therapy was performed as anti-amblyopic treatment as necessary.

#### STATISTICAL ANALYSES

Mann–Whitney and Fisher's exact tests were used for comparison of continuous and categorical baseline variables, respectively. The Wilcoxon signed rank test was applied to detect changes from baseline parameters. Statistical analyses were performed using IBM Statistical Package for the Social Sciences statistics software, version 20 (SPSS, IBM Corp, Armonk, NY, USA).  $P$  values  $< 0.05$  on a two-sided test were considered statistically significant.

#### RESULTS

We reviewed records of 37 pediatric patients diagnosed with unilateral traumatic cataracts. We included in this study 18

children who completed a minimum follow-up of 5 years and without a posterior segment involvement. Baseline characteristics of the patients and the trauma etiologies can be found in Table 2 (online version only). The mean follow-up time was 12.5 years (range 5–30). Median age at injury was 7.5 years (range 2.6–17). Fifteen patients (83%) were boys and three (17%) were girls (male/female ratio 5:1). Sixteen patients (89%) were diagnosed with cataracts at admission (10 from the penetrating trauma group and 6 from the blunt trauma group). The other two patients (11%), one with penetrating and the other with blunt trauma, developed cataracts during their follow-up periods.

Cataract removal surgery was conducted on 16 patients, including an IOL implant in 14 (87.5%), 6 during the primary lensectomy procedure and 8 during a secondary procedure. Two patients remained aphakic (12.5%) due to a much more severe initial injury. Their vision was corrected with contact lenses. In two patients (11%) we opted for conservative management without cataract removal surgery since the ocular injury was severe and we deemed that visual acuity would not improve following surgery.

The average final visual acuity was 20/40 (range light perception 20/20) in the pseudophakic group and 20/2000 (range hand movement-counting fingers) in the aphakic group. The mean final visual acuity was 20/63 in the dislocated group and 20/32 in the non-dislocated group. The percentage of patients who achieved visual acuity better than 20/40 was higher in the blunt trauma group compared to the penetration group (100% vs. 60%,  $P = 0.04$ ).

There was no correlation between final visual acuity and the time interval between injury and intraocular lens implantation nor between final visual acuity and age at trauma. However, the final visual acuity did correlate with time of follow-up ( $r = 0.51$ ,

$P = 0.03$ ). Every year of follow-up led to 0.05 deterioration in logMAR visual acuity.

### COMPLICATIONS

Patient characteristics according to trauma type (penetrating or blunt trauma) and age at the time of injury are summarized in Table 2 (online version only), including follow-up time. Posterior capsular opacification appeared earliest, as soon as 3 days after the injury, while intraocular lens dislocation was diagnosed as much as 12 years later [Table 3 (online version only)].

Complication rates were comparable between the trauma groups (penetration vs. blunt), as no comparison was significantly different [Table 3 (online version only)].

As expected, a high incidence 10/14 (71%) of posterior capsular opacification (PCO) was seen in pediatric patients implanted with an IOL. In the penetrating trauma group, 6/8 (75%) patients developed PCO, compared to 4/6 (67%) patients in the blunt trauma group ( $P = 0.91$ ). In addition, no difference was found between penetrating and blunt trauma in relation to the age groups ( $P = 0.70$ ). During follow-up, a posterior capsular opening was performed on nine patients (seven by Nd:YAG-laser and two by surgical – pars plana membranectomy). All eyes maintained a clear central visual axis. The IOL dislocations rate was also comparable between the penetrating trauma group 4/8 (50%) and the blunt trauma group 1/6 (17%), ( $P = 0.2$ ). Glaucoma rates were also similar between the groups: 5/11 (45%) in the penetrating trauma compared to 2/7 (29%) in the blunt trauma group ( $P = 0.5$ ). It should be noted, however, that the two aphakic patients (100%) developed glaucoma, as compared to only 4/14 (29%) ( $P = 0.06$ ) of the pseudophakia patients and 1/2 (50%) of those patients who did not undergo any surgery ( $P$  non-significant). Synechia formation was also statistically similar in both groups, 4/7 (57%) in blunt trauma, as compared to 2/11 (18%) in the penetrating trauma group ( $P = 0.09$ ). Cosmetically apparent strabismus was found in one aphakic patient from the penetrating trauma group. Retinal detachments requiring further surgeries were only observed twice in the penetrating trauma group, one pertaining to each subgroup (pseudophakic and aphakic).

### DISCUSSION

In this study, we evaluated the complications and visual outcomes of children with unilateral traumatic cataracts. This group of 18 children, chosen from a larger group of 37, satisfied our restrictive criterion of having had a minimum follow-up of at least 5 years. These children had a long-term follow-up of 12.5 years (mean), which makes this one of the longest in Israel.

Our case series showed male predominance among those with traumatic cataracts (85%), which is consistent with previous reports [11,12]. We showed that the interval between trauma and IOL insertion was not related to visual outcome.

Therefore, delaying lens surgery could afford the surgeon the opportunity to better evaluate the eye and its healing capabilities following an injury, without affecting the final outcome [13]. Postponing cataract surgery means operating on a clearer and quieter media after the perforation wounds have healed. In addition, it allows for a more precise IOL calculation, the removal of corneal sutures by refraction, and the implantation of a toric lens, if necessary [14]. Some studies have reported that the longer the interval between cataract development and surgery, the greater the risk for amblyopia [15]. According to our data and to previous studies, there was no correlation between this time interval and final visual acuity [11,14]. This is most probably due to more intensive treatment and follow-up to prevent amblyopia in those children.

We also demonstrated that the age of the child was not related to final visual outcome. However, the age of the child also played a role in the decision-making as IOL implantations are usually not recommended for infants younger than one year of age as they tend to develop dense fibrinoid membranes [13]. In addition, a uveitic reaction is known to be more intense the younger the child is at the time of injury. Kugelberg and colleagues [16] showed that in pseudophakic pediatric patients, exaggerated inflammatory reaction may be caused by uveal compression (a large intraocular lens in a small, child-sized eye).

IOL implantation was generally well-tolerated, with reduced tendency toward glaucoma, retinal detachment, and strabismus. The trend was similar to that described by BenEzra [17] who found better visual acuities and less strabismus among pseudophakic children than among aphakic ones with contact lenses.

The effect of intraocular lens implantation on the incidence of glaucoma after pediatric cataract surgery still remains unclear [18]. Glaucoma has been recognized as a significant complication of pediatric cataract extraction, especially without subsequent intraocular lens implantation [19,20]. Studies have noted a low incidence of glaucoma in pseudophakic children compared to aphakic ones [21,22]. The mechanism causing aphakic glaucoma is still unknown. However certain theories have been suggested, including an increased inflammatory response, the presence of residual lens material, and a chemical vitreous component [18]. Others assume that angle recession glaucoma may originate after the initial trauma and that pseudophakia may somehow have a protective effect [20].

Retinal detachment was seen in two of our patients from the penetrating trauma group, one with and one without an IOL implantation. We assume that these retinal detachments were associated with the mechanisms of the traumas themselves [23]. Previous studies have suggested that chronic inflammation due to delayed reabsorption of lens materials may also play a role in causing retinal detachment pathogenesis after trauma [24]. Since a child's vitreous is well-formed, retinal detachment tends to appear relatively late in the course of follow-up [25].

We noted that higher percentages of patients in the blunt trauma group achieved excellent visual outcome (visual acuity  $\geq 20/40$ ) than members in penetrating trauma group. This difference may be explained by the higher percentage of post-operative complications in the penetrating trauma group than in the blunt trauma.

As shown in our study, the time interval between the trauma and the development of a complication greatly varied, sometimes seen as soon as days after the injury, other times only appearing many years after the operation. This requires close follow-up necessitating discussion between the operating physician and the parents regarding the long-term prognosis. The strength of our study is in its long follow-up periods. Its limitations are a small number of patients and its being a retrospective-type cohort study.

## CONCLUSIONS

Children with traumatic cataracts but no initial damage to the posterior segment tend to have favorable long-term results (especially with blunt trauma, 100% achieved visual acuity  $> 20/40$ ). However, severe complications occurred in over 30% of patients during the long follow-up (mean 12.5 years). Complications may even arise years after an uneventful post-operative period. This emphasizes the need for a discussion between the operating physician and the parents regarding the prognosis and necessity of scheduled follow-ups in a child with traumatic cataract.

## Correspondence

Dr. A. Hilely

Dept. of Ophthalmology, Kaplan Medical Center, Rehovot 76100, Israel  
email: Hilely@hotmail.com

## References

- Shah MA, Agrawal R, Teoh R, et al. Pediatric ocular trauma score as a prognostic tool in the management of pediatric traumatic cataracts. *Graefes Arch Clin Exp Ophthalmol* 2017; 255 (5): 1027-36.
- Reddy A, Ray R, Yen KG. Surgical intervention for traumatic cataracts in children: epidemiology, complications, and outcomes. *J AAPOS* 2009; 13 (2): 170-4.
- Parks MM. Visual results in aphakic children. *Am J Ophthalmol* 1982; 94 (4): 441-9.
- Gradin D, Yorston D. Intraocular lens implantation for traumatic cataract in children in East Africa. *J Cataract Refract Surg* 2001; 27 (12): 2017-25.
- Shah MA SS, Appleware AH, Patel KD, Rehman RM, Shikhanje KA. Visual outcome of traumatic cataract in pediatric age group. *Eur J Ophthalmol* 2012; 22 (6): 956-63.
- Blumenthal M, Yalon M, Treister G. Intraocular lens implantation in traumatic cataract in children. *J Am Intraocul Implant Soc* 1983; 9 (1): 40-1.
- Hemo YB, BenEzra D. Traumatic cataracts in young children. Correction of aphakia by intraocular lens implantation. *Ophthalmic Paediatr Genet* 1987; 8 (3): 203-7.
- BenEzra D, Cohen E, Rose L. Traumatic cataract in children: correction of aphakia by contact lens or intraocular lens. *Am J Ophthalmol* 1997; 123 (6): 773-82.
- Moisseiev J, Segev F, Harizman N, Arazi T, Rotenstreich Y, Assia EL. Primary cataract extraction and intraocular lens implantation in penetrating ocular trauma. *Ophthalmology* 2001; 108 (6): 1099-103.
- Leiba H, Springer A, Pollack A. Ocular axial length changes in pseudophakic children after traumatic and congenital cataract surgery. *J AAPOS* 2006; 10 (5): 460-3.
- Reddy AK, Ray R, Yen KG. Surgical Intervention for traumatic cataract in children: epidemiology, complications and outcomes. *J AAPOS* 2009; 13 (2): 170-4.
- Smith D, Wrenn K, Stack LB. The epidemiology and diagnosis of penetrating eye injuries. *Acad Emerg Med* 2002; 9 (3): 209-13.
- Hiles DA, Cheng KP, Biglan AW. Aphakic optical correction with intraocular lenses for children with traumatic cataracts. *EUR J Implant Ref Surg* 1990; 2: 275-83.
- Rumelt S, Rehany U. The influence of surgery and intraocular lens implantation timing on visual outcome in traumatic cataract. *Graefes Arch Clin Exp Ophthalmol* 2010; 248: 1293-7.
- Gupta AK, Grover AK, Gurha N. Traumatic cataract surgery with intraocular lens implantation in children. *J Pediatr Ophthalmol Strabismus* 1992; 29 (2): 73-8.
- Kugelberg U, Zetterström C, Lundgren B, Syrén-Nordqvist S. Ocular growth in newborn rabbit eyes implanted with a poly(methyl methacrylate) or silicone intraocular lens. *J Cataract Refract Surg* 1997; 23: 629-34.
- BenEzra D, Cohen E, Rose L. Traumatic cataract in children: correction of aphakia by contact lens or intraocular lens. *Am J Ophthalmol* 1997; 123: 773-82.
- O'Keefe M, Fenton S, Lanigan B. Visual outcomes and complications of posterior chamber intraocular lens implantation in the first year of life. *J Cataract Refract Surg* 2001; 27 (12): 2006-11.
- Johnson DA, Parks MM. Cataracts in childhood: prognosis and complications. *Semin Ophthalmol* 1991; 6 (4): 201-11.
- Zwaan J, Mullaney PB, Awad A, al-Mesfer S, Wheeler DT. Pediatric Intraocular Lens Implantation. Surgical results and complications in more than 300 patients. *Ophthalmology* 1998; 105 (1): 112-19.
- Trivedi RH, Wilson ME Jr, Golub RL. Incidence and risk factors for glaucoma after pediatric cataract surgery with and without intraocular lens implantation. *J AAPOS* 2006; 10 (2): 117-23.
- Arsani S, Freedman S, Hasselblad V, et al. Does intraocular lens implantation prevent "aphakic" glaucoma in children? *J AAPOS* 2000; 4: 33-9.
- Keech RV, Tongue AC, Scott WE. Complications after surgery for congenital and infantile cataracts. *Am J Ophthalmol* 1989; 108: 136-41.
- Toyofuku H, Hirose T, Schepens CL. Retinal detachment following congenital cataract surgery. I. Preoperative findings in 114 eyes. *Arch Ophthalmol* 1980; 98: 669-75.
- Wenick AS, Barañano DE. Evaluation and management of pediatric rheumatogenous retinal detachment. *Saudi J Ophthalmol* 2012; 26: 255-63.

## Capsule

### Microbiota and age-related disease

Gut bacteria have been shown to influence numerous conditions including cancer, diabetes, and neurological diseases. **Bárcena** and co-authors explored how the microbiota affects aging by analyzing the gut microbiota of children with the premature aging disorder called progeria. Patients with accelerated aging displayed greater disturbances in their intestinal bacteria during disease progression when compared

with normally aging individuals. Using mouse models of aging, the researchers found that transplantation of fecal microbiota from healthy mice extended the life span of two different models of progeria. This effect correlated with the restoration of levels of secondary bile acids.

*Nat Med* 2019; 25: 1234

Eitan Israeli



**Table 1.** Summary of studies on pediatric traumatic cataract

Name	Year	Number of eyes	Follow-up time	VA $\geq$ 6/12
Shah et al.	2017	1070	4 months (3 months–1 year)	42%
Puri et al.	2015	189	3 months	67% ( $>$ 6/18)
Xu et al.	2013	117	10.64 $\pm$ 6.81 months	43%
Shaw et al.	2012	354	6 weeks	35%
Shah et al.	2011	687	1 year	33%
Reddy et al.	2009	25	13 months, (range 2–45 months)	8% ( $>$ 6/18)
Kamlesh et al.	2004	30	5 years (range 2–8 years)	80%
Sminia et al.	2007	5	11.0 years (range 8.0–14.6 years)	80%
Moisseiev et al.	2001	21	20.4 months (range 2–77 months)	67%
Gradin et al.	2001	215	20 weeks (39% $>$ 1 year)	43%
Pandey et al.	1999	20	24.6 months $\pm$ 10.6	85%
Zwaan et al.	1998	306	13 months (range 6 months–4 years)	44%
Krishnamachary et al.	1997	137	11.7 months (range 1 week–60 months)	74% ( $>$ 6/18)
BenEzra et al.	1997	40	7.4 years (range 1.5–11 years)	65% of pseudophakia
Ghosh et al.	1997	40	1.6 years (range 1–3)	$>$ 95% of epilateral group+PPV, 20% of ECCE+PCIOL
Menezo et al.	1994	103	1–15 years	77%
Gupta et al.	1992	22	6–15 months	45%
BenEzra et al.	1990	28	$>$ 12 years	77% of pseudophakic ( $>$ 6/15), 33% of contact lens treated ( $>$ 6/15)
Hiles et al.	1990	238	2–16 years	51%
Hemo et al.	1987	37	6–24 months	77% with primary IOL implantation 69% with secondary IOL implantation

ECCE = extracapsular cataract extraction, IOL = intraocular lens, PCIOL = posterior chamber intraocular lens, PPV = pars plana vitrectomy, VA = visual acuity

**Table 2.** Baseline characteristics of patients included in this study

Patients	Gender	Age at injury, years	Trauma etiology	Follow-up in years
1	Male	7	Penetrating	7
2	Male	6	Blunt (stone)	8
3	Male	2.5	Blunt	26
4	Male	3	Penetrating	8
5	Female	6	Penetrating (glass)	5
6	Female	3	Penetrating (stick)	30
7	Male	6	Penetrating	27
8	Male	16	Blunt (fruit from a rubber sling)	9
9	Male	17	Penetrating (iron nail)	8
10	Male	15	Penetrating (iron)	5
11	Male	9	Blunt (firecracker)	14
12	Male	10	Blunt	7
13	Male	8	Blunt (stick)	10
14	Male	12.5	Penetrating (rubber sling)	19
15	Male	9	Blunt	6
16	Male	3	Penetrating	10
17	Male	6	Penetrating (glass)	14
18	Female	10	Penetrating (glass)	12

**Table 3.** Complication rates according to sub-group with the time interval between the trauma and development of complications

Complication (Range)	Number of patients (%)					
	Penetrating n=11 (61%)			Blunt n=7 (39%)		
	Pseudophakia 8 (73%)	Aphakia 2 (18%)	Not operated 1 (9%)	Pseudophakia 6 (86%)	Aphakia 0 (0%)	Not operated 1 (14%)
Posterior capsular opacity (3 days–3 years)	6 (75%)	–	–	4 (67%)	–	–
Intraocular lens dislocation (1 month–12 years)	4 (50%)	–	–	1 (17%)	–	–
Retinal detachment (1–5 weeks)	1 (12.5%)	1 (50%)	–	–	–	–
Strabismus ( $<$ 5 years)	–	1 (50%)	–	–	–	–
Glaucoma (3 months–8 years)	3 (37.5%)	2 (100%)	–	1 (17%)	–	1 (100%)
Synechia formation (1 week–6 months)	2 (25%)	–	–	3 (50%)	–	1 (100%)

Complication rates were comparable between trauma group (penetration vs. blunt), as no comparison achieved statistically significant differences

**Additional references for Table 1, Table 2, Table 3**

1. Shah MA, Agrawal R, Teoh R, et al. Pediatric ocular trauma score as a prognostic tool in the management of pediatric traumatic cataracts. *Graefes Arch Clin Exp Ophthalmol* 2017; 255 (5): 1027-36.
2. Gradin D, Yorston D. Intraocular lens implantation for traumatic cataract in children in East Africa. *J Cataract Refract Surg* 2001; 27 (12): 2017-25.
3. Shah MA, Shah SM, Applegate AH, Patel KD, Rehman RM, Shikhanje KA. Visual outcome of traumatic cataract in pediatric age group. *Eur J Ophthalmol* 2012; 22 (6): 956-63.
4. Reddy AK, Ray R, Yen KG. Surgical intervention for traumatic cataracts in children: Epidemiology, complications, and outcomes. *J AAPOS* 2009; 13 (2): 170-4.
5. Hemo Y, BenEzra D. Traumatic cataracts in young children. Correction of aphakia by intraocular lens implantation. *Ophthalmic Paediatr Genet* 1987; 8 (3): 203-7.
6. Hiles DA, Cheng KP, Biglan AW. Aphakic optical correction with intraocular lenses for children with traumatic cataracts. *EUR J Implant Ref Surg* 1990 2: 275-83.
7. BenEzra D, Cohen E, Rose L. Traumatic cataract in children: correction of aphakia by contact lens or intraocular lens. *Am J Ophthalmol* 1997; 123 (6): 773-82.
8. Gupta AK, Grover AK, Gurha N, Traumatic cataract surgery with intraocular lens implantation in children. *J pediatr ophthalmol strabismus* 1992; 29 (2): p. 73-78.
9. Menezo JL, Esteve JT, Perez-Torregrosa VT. IOL implantation in children-17 Years' Experience. *Eur J Implant Ref Surg* 1996; 6 (5): 251-6.
10. Ghosh B, Gupta AK, Taneja S, Gupta A, Mazumdar S. Epilenticular lens implantation versus extracapsular cataract extraction and lens implantation in children. *J Cataract Refract Surg* 1997; 23 (Suppl 1): 612-7.
11. BenEzra D, Hemo I, Traumatic cataract in children. visual results following aphakic correction with contact or intraocular lenses. *Eur J Implant* 1990; 2 (4): 325-8.
12. Zwaan J, Mullaney PB, Awad A, al-Mesfer S, Wheeler DT, Pediatric intraocular lens implantation. Surgical results and complications in more than 300 patients. *Ophthalmology* 1998; 105 (1): 112-8.
13. Krishnamachary M, Rath V, Gupta S. Management of traumatic cataract in children. *J Cataract Refract Surg* 1997; 23 (Suppl 1): 681-7.
14. Pandey SK, Ram J, Werner L, et al, Visual results and postoperative complications of capsular bag and ciliary sulcus fixation of posterior chamber intraocular lenses in children with traumatic cataracts. *J Cataract Refract Surg* 1999; 25 (12): 1576-84.
15. Moisseiev J, Segev E, Harizman N, Arazi T, Rotenstreich Y, Assia EL. Primary cataract extraction and intraocular lens implantation in penetrating ocular trauma. *Ophthalmology* 2001; 108 (6): 1099-103.
16. Sminia ML, Odenthal MT, Wenniger-Prick LJ, Gortzak-Moorstein N, Völker-Dieben HJ., Traumatic pediatric cataract: a decade of follow-up after Artisan aphakia intraocular lens implantation. *J AAPOS* 2007; 11 (6): 555-8.
17. Kamlesh, Dadeya S., Management of paediatric traumatic cataract by epilenticular intraocular lens implantation: long-term visual results and postoperative complications. *Eye (Lond)* 2004 18(2): p. 126-30.
18. Shah, MA, Shah SM, Shah SB, et al., Comparative study of final visual outcome between open- and closed-globe injuries following surgical treatment of traumatic cataract. *Graefes Arch Clin Exp Ophthalmol* 2011; 249 (12): 81-1775.
19. Xu YN, Huang YS, Xie LX. Pediatric traumatic cataract and surgery outcomes in eastern China: a hospital-based study. *Int J Ophthalmol* 2013 18 (6): 160-4.
20. Puri LR, Shrestha GS. Visual outcome of cataract surgery with IOL implantation in traumatic cataract among 189 children: the Lahan experience. *J Chitwan Med College* 2015; 5 (3): 1-10.
21. Blumenthal M, Yalon M, Treister G. Intraocular lens implantation in traumatic cataract in children. *J Am Intraocular Implant Soc* 1983; 9 (1): 40-1.