

Blunt Chest Trauma with Disruption in the Intrathoracic Trachea

Yaacov Goykhman MD¹, Joseph Paz MD³, Edan Sarid MD², Joseph Klausner MD¹ and Dror Soffer MD^{1,2}

¹Division of Surgery B, ²Trauma Unit and ³Department of Thoracic Surgery, Tel Aviv Sourasky Medical Center, affiliated with Sackler Faculty of Medicine, Tel Aviv University, Ramat Aviv, Israel

KEY WORDS: tracheobronchial injury, blunt chest trauma

IMAJ 2010; 12: 770–772

Tracheobronchial injury following blunt chest trauma is a rare and potentially lethal injury that can be successfully repaired if early diagnosis is made. Many patients with traumatic rupture of the tracheobronchial tree die before reaching the hospital. Failure to recognize an injury to the upper airway may be life threatening in the acute phase and may lead to severe long-term morbidity related to phonation and airway patency. We report the case of a 22 year old man with intrathoracic blunt tracheal injury.

PATIENT DESCRIPTION

A 22 year old previously healthy man was admitted to our hospital by an emergency paramedic team following a high-speed frontal motor vehicle collision resulting in multiple traumatic injuries. The emergency team reported that the patient was a passenger in the vehicle and had been using the seat belt. Significant intrusion into the passenger compartment led to prolonged extraction time.

At the scene of the accident, the patient was alert, hemodynamically stable and was noted to be dyspneic (respiratory rate 20, SaO₂ 90%). Signs of severe maxillofacial injury were observed at the scene. At presentation in the Emergency Department, the patient had a patent airway but had signs of severe facial injury.

He was alert (Glasgow Coma Scale score 15), tachypneic with a respiratory rate of 25 breaths/min and an oxygen saturation of 93% with supplemental oxygen at 10 L/min. Auscultation of the lungs revealed mildly diminished breath sounds on the left side and normal breath sounds on the right, without obvious chest deformity or signs of tension pneumothorax. His systolic blood pressure was 120 mmHg and his pulse 100 beats/min. Abdominal and neurological examinations were normal.

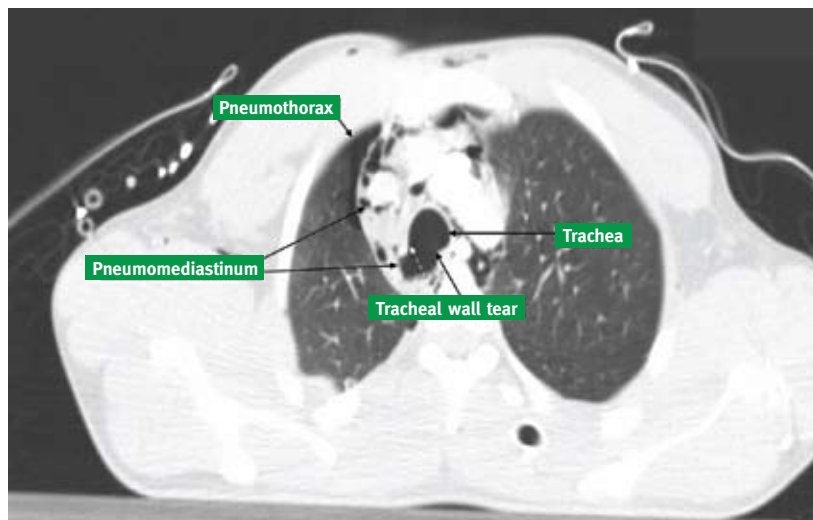
Initial resuscitation and preventive orolaryngeal intubation were performed by inserting an endotracheal tube with a rapid sequence induction. This was followed by a supine chest X-ray that revealed a small left pneumothorax and pneumomediastinum. After several minutes, progressive subcutaneous emphysema appeared and an intercostal chest

drain was immediately inserted; only a small amount of air was drained. The routine laboratory tests were within normal range. Subsequent workup included a computed tomography scan of the head, neck, chest and abdomen.

Head CT revealed "Le-Fort" fractures type II of the middle face that involved the maxillary dentoalveolar segment with suspicion of entrapment of the inferior direct ocular muscle, bilateral condylar fractures and left parasymphyseal mandibular fractures. There were no signs of bleeding, midline shift or pressure signs.

Chest CT revealed pneumomediastinum, right pneumothorax and lung contusion, and a suspected 4.5 cm tear of the right posterior wall of the trachea 2.8 cm above the carina [Figure]. Signs of esophageal injury were ruled out and verified by a contrast material study.

Chest CT showing pneumomediastinum, right pneumothorax, lung contusion, and a 4.5 cm tear of the right posterior wall of the trachea -2.8 cm above the carina



Abdominal CT showed no evidence of traumatic injury.

The patient remained stable and a right intercostal chest drain was inserted with further drainage of small amounts of air. Bronchoscopy was then performed and demonstrated a blood clot protrusion at 2 cm above the carina on the right posterior tracheal wall, suspicious for a tracheal tear. The patient was then transferred directly to the operating room. On arrival, he continued to be in stable condition. Flexible esophagoscopy did not reveal any injury. A right posterolateral thoracotomy was performed, exposing the isolated tear of the membranous part of the trachea 6 cm long without airway devascularization. The laceration was repaired primarily with simple interrupted absorbable sutures. The patient was then transferred to the intensive care unit. The postoperative course was uneventful. He was discharged on postoperative day 18 for rehabilitation and his follow-up did not reveal any delayed complications. The outpatient follow-up was based solely on the clinical picture and was normal.

COMMENT

Traumatic tracheobronchial injuries are an uncommon but life-threatening occurrence. These injuries are often fatal because of the compromised ventilation. The infrequency and occult clinical nature of such injuries often result in a delay in diagnosis. Currently, the most common cause of tracheobronchial injury is iatrogenic injury after intubation or tracheotomy procedures. During recent decades, an increase in traffic accidents has caused an increase in blunt tracheobronchial injuries. The exact mechanism of intrathoracic tracheobronchial disruption from blunt trauma is unknown but, as discussed, 80% of these injuries include longitudinal lacerations of the distal trachea at or near the carina (usually within 2.5 cm), with complete or partial disruption of the main bronchus (more common on the right) [1,3] and other lobar bronchi.

Three hypotheses explain the mechanism of non-iatrogenic, non-penetrating tracheobronchial injury. The first hypothesis suggests that excessive pressure in the bronchial tree when the glottis is closed causes airway blowout at the point of greatest diameter – the carina – in accordance with Laplace's law. Rupture in these circumstances can occur when the intraluminal pressure exceeds the elasticity of the membranous trachea and bronchi and occurs most commonly at the junction of the membranous and cartilaginous airway. A second hypothesis is that as the anterior-posterior diameter decreases the lateral chest diameter increases, and while the lungs are pulled out laterally the main bronchi and carina become disrupted. Airway disruption occurs if this lateral force exceeds tracheobronchial elasticity. According to the third hypothesis, because the carina is tethered, severe and sudden deceleration can give rise to sheer forces that may disrupt the airway at points of relative fixation such as the cricoid cartilage and the carina, similar to the mechanism of traumatic injuries of the thoracic aorta [2].

Because of the magnitude of blunt trauma necessary to produce an airway injury, associated injuries are also common in this group and may be the primary determinant in patient outcome. Airway injuries become the first priority in trauma, and because of their acuity and critical importance in stabilizing the patient, initial steps in management may precede simultaneously with the diagnosis of airway pathology and associated injuries. Common symptoms are dyspnea and respiratory distress, hoarseness or dysphonia. The most common signs of airway injury reported in most series were subcutaneous emphysema (35–85%), pneumothorax (20–50%), and hemoptysis (14–25%).

The most useful initial diagnostic studies are those obtained routinely in the initial trauma survey (i.e., chest and cervical spine radiographs). Radiographic frequent signs are deep cervical emphysema, pneumomediastinum and pneu-

mothorax. The cervical spine or chest X-ray may also show a disruption of the tracheal or bronchial air column on careful examination. Complete transection of a mainstem bronchus may result in the classic signs of atelectasis, "absent hilum," or a collapsing of the lung away from the hilus toward the diaphragm, known as the "falling lung sign of Kumpe." A persistent pneumothorax with large air leak from a well-placed chest tube should increase the suspicion of intrathoracic tracheal or bronchial injury.

Although neck and upper chest CT scan has become critical to the accurate diagnosis of traumatic laryngeal injuries, its role in more distal tracheobronchial injuries is not well established. The CT scan may show mediastinal air, disruption of the tracheobronchial air column, deviation of the airway, or the specific site of airway disruption. A negative CT scan does not obviate the need for bronchoscopy or other diagnostic studies. CT bronchography, or virtual bronchoscopy, may be helpful in some cases [1]. Bronchoscopy provides the single definitive diagnostic study in a patient with suspected airway injury. Bronchoscopy is the only study that can reliably exclude central airway trauma, although minor lacerations may occasionally be missed.

The initial and most important priority in acute tracheobronchial injury is to secure a satisfactory airway. Patients with respiratory distress and the clinical suspicion of an airway injury should be intubated immediately, preferably with the guidance of a flexible bronchoscope.

On occasion, injuries will be found that do not require operative repair. These include small injuries, primarily mucosal, which are not associated with significant ongoing air leak or distal obstruction. These lesions typically are smaller than one-third of the entire circumference and should not be associated with tissue devitalization. These injuries still require follow-up as late stricture and related complications can occur [1].

The traditional treatment for tracheobronchial injury has been surgery.

Management is determined by location, extent of injury, and associated injuries. The proximal one-half to two-thirds of the trachea is best approached through a low cervical collar incision that also provides excellent exposure to vascular or esophageal injuries in the neck. Creating a "T" incision over the manubrium and splitting the manubrium down to the second interspace opens the thoracic inlet and provides a broader exposure to the middle third of the trachea as well as proximal control of the innominate artery or veins. The distal third of the trachea, the carina, and the right mainstem bronchus are most easily approached through a right thoracotomy, which also provides good exposure to the azygous vein, superior vena cava, and right atrium, as well as the entire intrathoracic esophagus. Injuries of the left mainstem bronchus are most easily approached through a left thoracotomy, which also provides good exposure to the distal portion of the aortic arch, the descending thoracic aorta, and the proximal left subclavian artery. However, exposure of the proximal left mainstem, the carina, the distal trachea, or the right mainstem is extremely difficult through a left thoracotomy, owing to the overlying aortic arch. Adequate proximal exposure may be gained by mobilization of the arch with retraction cephalad laterally and division of the ligamentum arteriosum.

Simple clean lacerations without airway devascularization can be repaired

primarily with simple interrupted absorbable sutures. In cases of significant tracheobronchial damage, all devitalized tissue should be debrided, with care taken to preserve as much viable airway as possible. In these cases, a circumferential resection and end-to-end anastomosis is almost always preferable to partial wedge resections of traumatized airway with attempted primary repair. The principles of airway resection and reconstruction are similar for tracheal, carinal or bronchial injuries, although the anatomy of reconstruction is unique to the surgical exposure, the location, and the extent of resection. Dissection of the airway is limited to the region to be resected to preserve tracheobronchial blood supply to the area of anastomosis. Intrathoracic tracheobronchial suture lines are also preferably wrapped with pedicled pericardial fat, intercostal muscle, or pleura to separate the airway anastomosis from overlying blood vessels [1].

The complications of tracheobronchial repair are similar to those of airway resection and reconstruction and consist mostly of anastomotic problems. Anastomotic dehiscence or restenosis occurs in 5–6% of patients after tracheal reconstruction [1]. Other rare complications are tracheal/innominate artery fistula or tracheoesophageal fistula.

In patients with early definitive airway repair the long-term good outcome occurred in more than 90%. Mortality

varies from 4% to 30% in the literature. The mortality rate is higher in patients with blunt rupture than in those with penetrating rupture [5]. The ultimate prognosis after blunt airway injury is dependent on the associated blunt injuries [5].

Most studies emphasize the importance of early diagnosis and surgical intervention. A prompt diagnosis is essential for better management and delay should not exceed 12 hours [4]. A high index of suspicion is essential for rapid diagnosis and early surgical intervention in patients with tracheobronchial injuries.

Corresponding author:

Dr. D. Soffer

Division of Surgery B, Tel Aviv Sourasky Medical Center, 6 Weizmann Street, Tel Aviv 64239, Israel

Phone: (972-3) 697-4711

Fax: (972-3) 697-4635

email: drors@tasmc.health.gov.il

References

1. Feliciano DV, Mattox KL, Moore EE. Trauma, chapter 27. 6th edn, New York: McGraw-Hill, 2008: 553-61.
2. Huh J, Milliken JC, Chen JC. Management of tracheobronchial injuries following blunt and penetrating trauma. *Am Surg* 1997; 63(10): 896-9.
3. Richardson JD. Outcome of tracheobronchial injuries: a long-term perspective. *J Trauma* 2004; 56: 30-6.
4. Cassada DC, Munyikwa MP, Moniz MP, Dieter RA Jr, Schuchmann GF, Enderson BL. Acute injuries of the trachea and major bronchi: importance of early diagnosis. *Ann Thorac Surg* 2000; 69: 1563-7.
5. Balci AE, Eren N, Eren S, Ülkü R. Surgical treatment of post-traumatic tracheobronchial injuries: 14-year experience. *Eur J Cardiothoracic Surg* 2002; 22: 984-9.