



Assessment of Coronary Artery Bypass Grafts by Cardiac Computed Tomography Angiography

Elisha Bar-Meir MD¹, Abd-El-Rauf Zeina MD¹, Jorge Blinder MD³ and Uri Rosenschein MD²

¹Department of Radiology & MAR Imaging Institute and ²Department of Cardiology, Bnai-Zion Medical Center, Haifa, Israel

³MAR Imaging Center, Bikur Cholim Hospital, Jerusalem, Israel

IMAJ 2005;7:275-276

A 61 year old overweight man with essential hypertension and ischemic heart disease was referred by his consultant cardiologist to our department for cardiac computed tomography angiography examination. Thirteen years previously he underwent coronary artery bypass graft surgery, which included three aorta-venous grafts to the right coronary artery, circumflex coronary artery and left marginal artery as well as a left internal mammary artery bypass graft to the distal left anterior descending artery.

The cardiac CTA study showed a patent LIMA bypass graft to the LAD, and a patent aorta-coronary venous graft to the LCX with a functioning distal anastomosis [Figures 1-3]. The remaining aorta coronary venous grafts were not visualized due to complete thrombosis.

The new generation multi-slice CT scanners are equipped with a large number of thinner detector rows, allowing reliable non-invasive detection of coronary artery disease [1,2]. Recent publications have shown that this new technology is accurate in differentiating between patent and occluded coronary artery bypass grafts, and in detecting graft stenosis [3-5].

The cardiac CTA study was performed using a multi-detector 16 row CT scanner (General Electric lightspeed-Pro, USA). The patient's heart rate was 60 beats per minute, obtained by the oral administration of a beta-blocker (atenolol, Normiten[®], 50 mg) 4 hours prior to the examination.

CTA = computed tomography angiography
LIMA = left internal mammary artery bypass
LAD = left anterior descending artery
LCX = circumflex coronary artery

Technique

Initial scout frontal and lateral images are usually obtained and the position of the heart is identified. An unenhanced CT scan through the chest is achieved to confirm the location of the heart and coronary bypass grafts. This is followed by a bolus timing study to determine the scanning delay required, by administering intravenously 10 ml non-ionic contrast medium. A total dose of 70 ml non-ionic contrast medium (Ultravist, Schering, Germany) is administered through an antecubital vein using a power injector at a rate of 4 ml/sec, followed by 50 ml saline injected immediately, for contrast dilution. The actual scanning time in a 16 detector multi-slice CT is 20 seconds.

Image reconstruction is performed by using the retrospective electrocardiographic gating method. Post-processing includes reconstruction of the images at a resolution of 0.6 x 0.6 x 0.625 mm, at phases 70%, 75% and 80% of the R-R interval. Images of the global native coronary arteries and coronary bypass grafts are reconstructed, using 3D-volume rendering and curved maximum intensity projection reformations.

Comment

The extent of coronary artery disease in patients after coronary bypass surgery is often underevaluated clinically, due to the invasiveness of conventional angiography examinations and the degenerated and diffusely calcified vessels. These patients seem well suited for diagnosis by non-

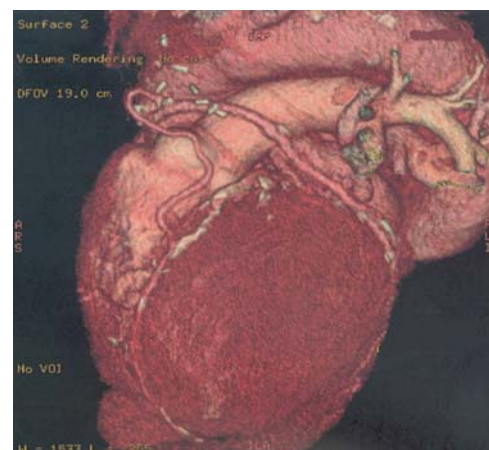


Figure 1. Cardiac CTA study for the evaluation of coronary artery bypass grafts. Left anterior volume-rendered view reconstructed at 70% of the cardiac cycle, demonstrating a LIMA bypass graft to the LAD and aorto-coronary venous graft to LCX. Note the occluded and calcified native arteries.

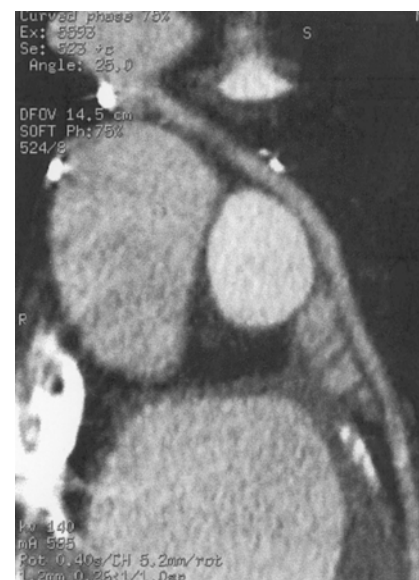

Figure 2. Curved maximum intensity projection (MIP) coronary artery reformat image shows patent venous-LCX graft.

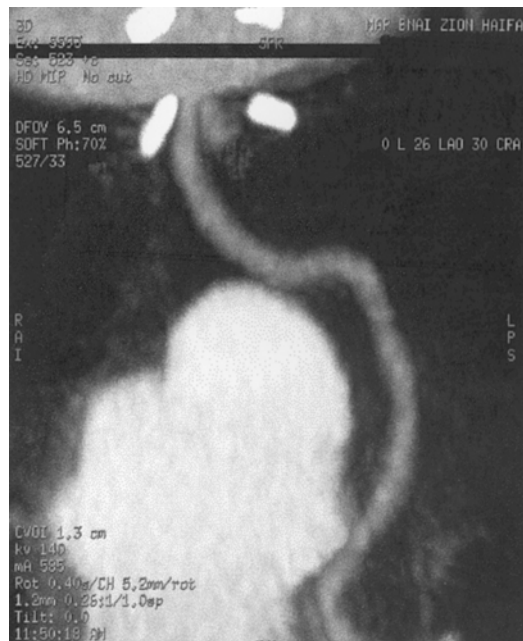

Figure 3. Patent LIMA-LAD graft. Note that the surgical clips at the anastomosis do not cause any metallic artifact.

invasive cardiac CTA because the grafts are characterized by less cardiac motion, a wide luminal diameter and fewer calcifications [4]. Using this novel method these factors contribute to a reliable assessment of the bypass grafts.

Technical improvements in the new-generation multi-slice CT systems have

led to shorter breath-hold times (reducing respiratory artifacts), faster rotation of the gantry (reducing cardiac motion artifacts), and a decreased slice thickness (resulting in better spatial resolution). The high sensitivity (96%) and specificity (95%) of this new imaging technique, and a negative predictive value of 99% [3] demonstrate that this method allows a reliable differentiation between patent and occluded coronary artery bypass grafts and an accurate detection of graft stenosis. A general drawback of multi-slice CT scanners is exposure to a relatively high radiation dose. However, in the recent-generation scanners the manufacturers have significantly

reduced the effective dose. Schlosser et al. [4] concluded that the ability to perform a non-invasive

procedure without hospitalization, combined with the excellent diagnostic accuracy, compensate for the radiation dose. In conclusion, the high sensitivity and negative predictive value prove that this method can be used in clinical routine as a non-invasive study for evaluating patients with suspected bypass graft dysfunction.

Acknowledgment. The authors wish to thank Roman Zimam PhD, from the General Electric Company, for his technical assistance.

References

1. Schoenhagen P, Halliburton SS, Stillman AE, et al. Noninvasive imaging of coronary arteries: current and future role of multi-detector row CT. *Radiology* 2004;232:7-17.
2. Kuettner A, Trabold T, Schroeder S, et al. Noninvasive detection of coronary lesions using 16-detector multislice spiral computed tomography technology. *J Am Coll Cardiol* 2004;44:1230-7.
3. Dewey M, Lembcke A, Enzweiler C, et al. Isotropic half-millimeter angiography of coronary artery bypass grafts with 16-slice computed tomography. *Ann Thorac Surg* 2004;77:800-4.
4. Schlosser T, Konorza T, Hunold P, et al. Noninvasive visualization of coronary artery bypass grafts using 16-detector row computed tomography. *J Am Coll Cardiol* 2004;44:1224-9.
5. Khan MF, Herzog C, Landenberger K, et al. Visualization of non-invasive coronary bypass imaging: 4-row vs. 16-row multidetector computed tomography. *Eur Radiol* 2005; 15:118-26.

Correspondence: Dr. E. Bar-Meir, Chairman, Dept. of Radiology, Bnai Zion Medical Center, P.O. Box 4940, Haifa 31048, Israel.
Phone: (972-4) 835-9320
Fax: (972-4) 825-3455
email: barmar@zahav.net.il