

## The Diabetic Charcot Foot

Robert A. Slater DPM, Yoram Ramot MD, Andreas Buchs MD and Micha J. Rapoport MD

Diabetes Unit, Assaf Harofeh Medical Center, Zerifin, Israel

Affiliated to Sackler Faculty of Medicine, Tel Aviv University, Ramat Aviv, Israel

**Key words:** Charcot foot, diabetes, neuropathy, neuroarthropathy, neuropathic osteoarthropathy, neurotrophic joint, pedal deformity, ulceration

IMAJ 2004;6:280–283

Undiagnosed and untreated diabetic neuroarthropathy (Charcot foot) is one of the more devastating complications of diabetes mellitus. Its insidious and frequently rapid progression can lead to severe deformity, instability, and amputation. Since the prevention of these disastrous consequences depends upon early detection and timely intervention, it behooves all clinicians who treat diabetic patients to understand and recognize this increasingly prevalent condition.

### History and epidemiology

Neuroarthropathy is a sometimes slow and sometimes extraordinarily rapid process in which joint effusion, dislocation, resorption of bone, and pathologic fracture can cause severe destruction of joints and the morphology of the foot. The entity, also known as neuropathic osteoarthropathy or neurotrophic joint, occurs as a complication secondary to a number of diseases that cause peripheral neuropathy [1–4]. First described by W. Musgrave in 1703, this entity has been associated most prominently with J.M. Charcot, who, in 1868, was the first to propose an etiology for the severe joint destruction seen in patients with tabes dorsalis [1]. Today diabetes is by far the leading cause of neuroarthropathy in developed countries, with as many as 13% of all diabetic patients and 29% of the neuropathic patients affected [1,3,5–7]. In the United States alone there are an estimated 375,000 patients with diabetic neuroarthropathy [8].

### Pathogenesis

Two competing theories have been proposed to explain the pathogenesis of diabetic neuroarthropathy. The neurovascular theory views this condition as a neurologically mediated trophic defect resulting in increased osseous blood supply and osteoclastic activity in the absence of injury or repetitive microtrauma [3,9,10].

The neurotraumatic theory proposes that neuroarthropathy occurs when a bone or joint has lost its protective sensation and then enters

a cycle of repetitive, excessive extension of ligaments and microfractures with increasing and often rapid disintegration of joints from continued weight-bearing [1]. The frequent findings of neuropathic ulcerations and increased pressures on the plantar aspect of the forefoot in acute diabetic neuroarthropathy support this theory [1,7,11–13].

Since neither of these theories can fully explain all cases of neuroarthropathy, such as its occurrence in paraplegic patients or its frequent onset following trauma, it is widely held today that both processes interact in varying degrees in the pathogenesis of this entity [Figure 1] [1,3,4,12,14].

### Clinical presentation

Acute diabetic neuroarthropathy may evolve slowly over many months or develop rapidly within weeks [3,5]. The process begins with a hyperemia usually following trauma to the foot or ankle [14]. The trauma is often mild and may not even be recalled by the patient [1,3,4,7]. Not infrequently there may be a delay of several months between the trauma and the incipient neuroarthropathy [1]. Classical clinical findings are an edematous, warm foot with bounding pulses and a severe peripheral neuropathy. The normal

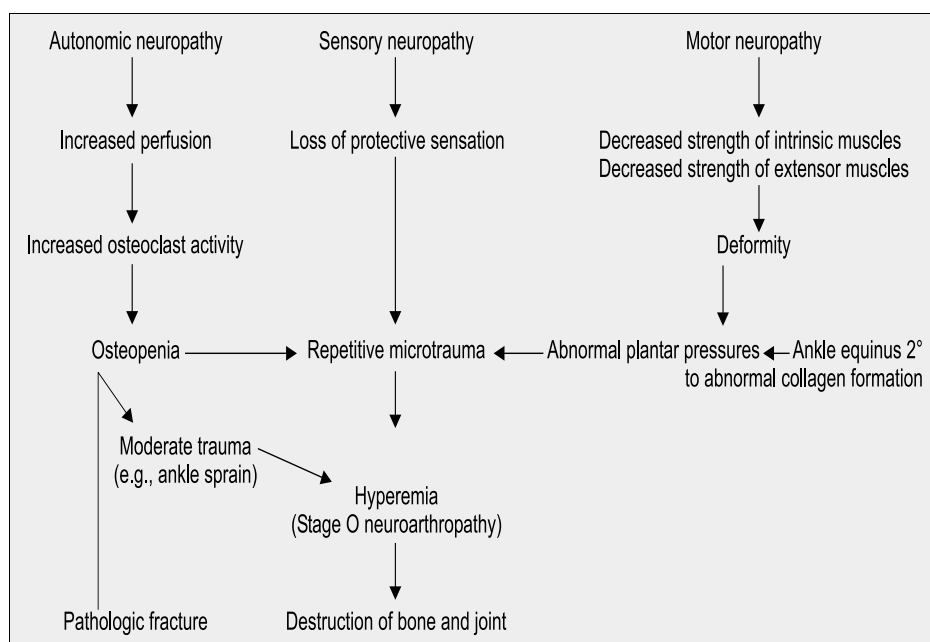


Figure 1. Unified theory of the pathogenesis of diabetic neuroarthropathy

architecture of the foot may be disturbed and plantar ulceration at the site of deformity may be present. Most patients complain of pain, but the complaints are usually less than would be expected from the clinical findings [1,3,4]. Men and women are equally affected. Most patients are in the mid-fifties, but neuroarthropathy can occur at any age [1]. Unilateral development is most common, but a significant number of patients can develop bilateral involvement [1,12]. Patients with long-standing (>10 years) and poorly controlled diabetes, neuropathy, history of ulceration, recent history of trauma, prior neuroarthropathy, or renal transplantation are high risk and should be watched closely since early clinical findings may be mild [1]. Infection, deep venous thrombosis, gout, trauma, or inflammatory arthritis should be excluded [1,3,6,14].

### Assessment

Diagnostic imaging is indicated primarily to evaluate the extent of bone and joint destruction or to detect osteomyelitis in a patient with clinical presentation consistent with acute neuroarthropathy. Standard radiographs should be taken at baseline and periodically thereafter to monitor progress. Ruling out osteomyelitis is difficult and may require imaging modalities including In-111 and Tc-99m HMPAO labeled leukocyte scans, computerized tomography and magnetic resonance imaging [14–16]. If doubts persist after examination and imaging, then a definitive diagnosis may be obtained by bone biopsy [1].

In the quiescent state, there are two concerns when assessing the deformity: are the ankle and the foot stable for ambulation and is there an increased risk of neuropathic ulceration? Furthermore, the vascular status of the patient should not be taken for granted. Although the acute state of neuroarthropathy requires good perfusion, during the post-acute state many patients can develop significant vascular disease of the lower extremity [12,17,18].

Ulceration and infection are often secondary complications of acute and quiescent diabetic neuroarthropathy. The standard principles of wound care apply to these ulcerations as they do to all wounds [19,20].

### Classification

A number of different systems have been used to classify diabetic neuroarthropathy. Eichenholtz proposed a three-stage system (development, coalescence, and remodeling) based solely upon

**Table 1.** Common clinical classification systems of neuroarthropathy

System	Stage	Findings
Eichenholtz	Development (1)	Subluxation, osteolysis, and fracture
	Coalescence (2)	Resorption of debris, fusion of fractures
	Remodeling (3)	Healing and hypertrophic bone formation
Sella and Barette	0	Pain, edema, erythema, warmth
	1	Osteopenia, subchondral cysts, erosions, diastasis
	2	Subluxation
	3	Dislocation and joint destruction
	4	Healing and hypertrophic bone formation

**Table 2.** Sanders-Frykberg anatomical classification of neuroarthropathy

Pattern	Location	% of cases	Common findings
I	Forefoot	35	Atrophic destruction: resorption of metatarsal and phalangeal shafts, osteolysis, subluxation of metatarsophalangeal joints, plantar ulceration
II	Tarsometatarsal joint	30	Subluxation of metatarsal bases, Rocker-bottom deformity, plantar ulceration, chronic instability
III	Talonavicular, calcaneocuboid and naviculocuneiform joint	25	Osteolysis of naviculocuneiform joint, Rocker-bottom deformity, often found in conjunction with Pattern II
IV	Ankle joint	9	Extensive joint destruction, severe deformity and instability, risk of high level amputation
V	Calcaneus	1	No joint involvement, calcaneal insufficiency avulsion fracture

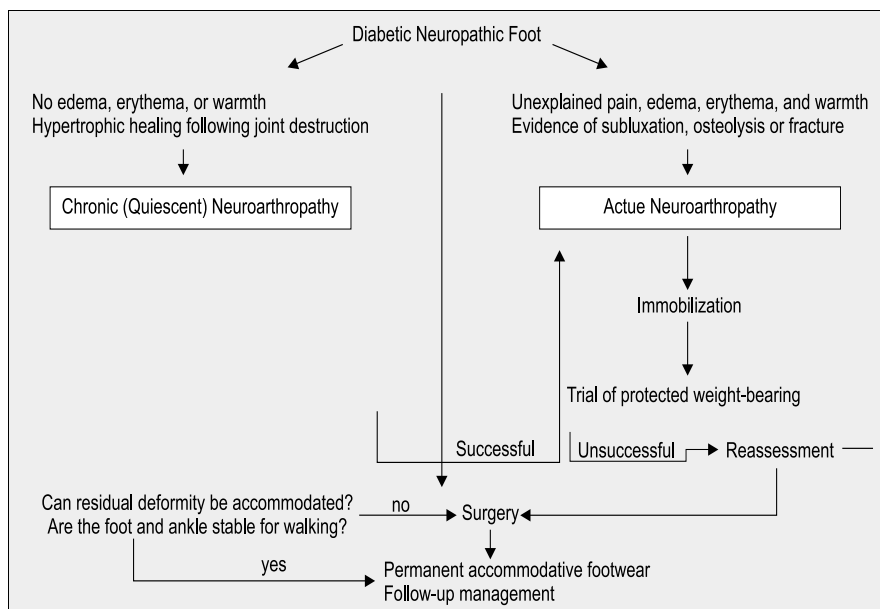
radiographic findings [Table 1] [1,4,14]. Since this classification system uses only radiographic findings, its usefulness is limited to cases where neuroarthropathy has become more advanced. Therefore, Sella and Barette [4] introduced a five-stage clinically oriented system ranging from mild local findings with minimal or no radiologic changes through major deformity and resolution [Table 1]. A pragmatic, treatment-based, two-stage system is also used in which the neuroarthropathy is acute, thus requiring immobilization, or quiescent, therefore allowing progressive, weight-bearing ambulation [4,7].

In addition, an anatomically oriented system, which divides the foot and ankle into five zones, has been found extremely useful in predicting prevalence and prognosis [Table 2] [1].

### Management

The goal of treatment in acute neuroarthropathy is to maintain the architecture of the foot and ankle while aiding the subsiding of the hyperemic process. The standard and most conventional technique is immobilization in a total contact cast [1,3,4,7,11,14,21,22]. Since the contralateral foot is at risk to develop acute neuroarthropathy, there is disagreement as to whether complete non-weight-bearing or protected weight-bearing is preferred when the affected foot is immobilized in a cast [1,3,7].

After immobilization in a cast, the patient should begin progressive weight-bearing in a removable cast-walker followed by a return to prescription footwear. The period needed for an acute neuroarthropathy to move into the quiescent phase varies, depending upon the extent and location of destruction. It may range from 2–3 months to as long as a year or more [1,7,14,22] with a mean time of 4–6 months [4]. Clinical judgment coupled with radiographic evidence of healing of fractures and a temperature



**Figure 2.** Algorithm for assessment and treatment of diabetic neuroarthropathy

difference of less than 1°C should guide the progression from immobilization to unassisted ambulation [1,22].

It is of interest that successful mid-foot arthrodesis in acute neuroarthropathy and the use of external fixation have been reported but need to be confirmed by larger trials [23,24]. Furthermore, reports of surgically induced diabetic neuroarthropathy should caution those who wish to use an invasive procedure during the acute phase [25]. Acute subluxation without fracture, however, is an exception in which surgery may be considered [1]. Recently, adjunctive treatments for acute diabetic neuroarthropathy were reported. In a double-blind randomized controlled trial of 39 patients, Jude et al. [21] found that bisphosphonate pamidronate, given as a single intravenous dose, leads to a reduction in bone turnover, symptoms and disease activity in diabetic patients with active neuroarthropathy. Several other treatments (magnetic fields, bone-growth stimulation, low intensity ultrasound, and palliative radiotherapy) have been reported anecdotally in the literature to be useful adjuncts [3,4].

If the acute phase is detected and treated early, patients will have little or no deformity in the quiescent state. Treatment in these patients is similar to that for diabetic neuropathic patients without a history of neuroarthropathy: namely, appropriate shoes and orthotics to disperse pressure and preserve the integrity of the skin and osseous morphology. Those patients with significant deformity will need special modifications or custom-molded shoes.

Re-constructive surgery may be considered in the quiescent state if deformity, instability, or ulceration persists despite custom shoes and orthotics [1,17]. Procedures for chronic ulceration include exostectomy, metatarsal head resection, and Achilles tendon lengthening [1,17,23]. Mid-foot fusion, triple arthrodesis, tibio-calcaneal fusion, or ankle fusion may be indicated to correct

chronic instability of the foot or ankle [1,18]. These procedures involve prolonged convalescence and a significant risk of complications that can result in a high level amputation [1]. An algorithm for the assessment and treatment of diabetic neuroarthropathy is presented in Figure 2.

## Conclusion

Diabetic neuroarthropathy is increasing in prevalence. All physicians treating diabetic patients should be vigilant in recognizing the early signs of an acute process such as unexplained pain, warmth, edema, or pathologic fracture in a neuropathic foot. Early detection and prompt treatment can prevent joint and osseous destruction, which may result in morbidity and high level amputation. Patients in the quiescent stage with significant deformity are at high

risk for amputation and should be referred to a diabetic foot clinic for management.

## References

- Sanders LJ, Frykberg RG. Charcot foot. In: Levin ME, O'Neal LW, Bowker JH, eds. *The Diabetic Foot*. St. Louis: Mosby, 1993:149–80.
- Sinha S, Munichoodappa CS, Kozak GP. Neuro-arthropathy (Charcot joints) in AS diabetes mellitus. *Medicine* 1972;51:191–210.
- Rajbhandari SM, Jenkins RC, Davies C, Tesfaye S. Charcot neuroarthropathy in diabetes mellitus. *Diabetologia* 2002;45:1085–96.
- Armstrong DG, Peters EJG. Charcot's arthropathy of the foot. *J Am Podiatr Med Assoc* 2002;92:390–4.
- Pogonowska MJ, Collins LC, Dobson HL. Diabetic osteopathy. *Radiology* 1967;89:265–71.
- Cavanagh PR, Young MJ, Adams JE, Vickers KL, Boulton AJM. Radiographic abnormalities in the feet of patients with diabetic neuropathy. *Diabetes Care* 1994;17:201–9.
- Armstrong DG, Todd WF, Lavery LA, Harkless LB, Bushman TR. The natural history of acute Charcot's arthropathy in a diabetic foot specialty clinic. *Diabetic Med* 1997;14:357–63.
- Childs M, Armstrong DG, Edelson GW. Is Charcot arthropathy a late sequela of osteoporosis in patients with diabetes mellitus? *J Foot Ankle Surg* 1998;37:437–9.
- Gough A, Abrahama H, Li F, et al. Measurement of markers of osteoclast and osteoblast activity in patients with acute and chronic diabetic Charcot neuroarthropathy. *Diabetic Med* 1997;14:527–31.
- Young MJ, Marshall A, Adams JE, Selby PL, Boulton AJM. Osteopenia, neurological dysfunction, and the development of Charcot neuroarthropathy. *Diabetes Care* 1995;18:34–8.
- Lavery LA, Armstrong DG, Walker SC. Healing rates of diabetic foot ulcers associated with midfoot fracture due to Charcot's arthropathy. *Diabetic Med* 1997;14:46–9.
- Fabrin J, Larsen K, Holstein PE. Long-term follow-up in diabetic Charcot feet with spontaneous onset. *Diabetes Care* 2000;23:796–800.
- Armstrong DG, Lavery LA. Elevated peak plantar pressures in patients who have Charcot arthropathy. *J Bone Joint Surg Am* 1998;80A:365–9.
- Yu GV, Hudson JR. Evaluation and treatment of stage 0 Charcot's neuroarthropathy of the foot and ankle. *J Am Podiatr Med Assoc* 2002;92:210–20.
- Seabold JE, Flickinger FW, Kao SCS, et al. Indium-111-leukocyte/Technetium-99m-MDP bone and magnetic resonance imaging: difficulty

- of diagnosing osteomyelitis in patients with neuropathic osteoarthropathy. *J Nuclear Med* 1990;31:549–56.
16. Croll SD, Nicholas GG, Osborne MA, Wasser TE, Jones S. Role of magnetic resonance imaging in the diagnosis of osteomyelitis in diabetic foot infections. *J Vasc Surg* 1996;24:266–70.
17. Rosenblum BI, Giurini JM, Miller LB, Chrzan JJ, Habershaw GM. Neuropathic ulcerations plantar to the lateral column in patients with Charcot foot deformity: a flexible approach to limb salvage. *J Foot Ankle Surg* 1997;36:360–3.
18. Myerson MS, Henderson MR, Saxby T, Short KW. Management of midfoot diabetic neuroarthropathy. *Foot Ankle Int* 1994;15:233–41.
19. Slater R, Ramot Y, Rapoport M. Diabetic foot ulcers: principles of assessment and treatment. *IMAJ* 2001;3:59–62.
20. Slater RA, Lazarovitch T, Boldur I, et al. Swab cultures accurately identify bacterial pathogens in diabetic foot wounds. *Diabetic Med* 2004. In press.
21. Jude EB, Selby PL, Burgess J, et al. Bisphosphonates in the treatment of Charcot neuroarthropathy: a double-blind randomised controlled trial. *Diabetologia* 2001;44:2032–7.
22. Armstrong DG, Lavery LA. Monitoring healing of acute Charcot's arthropathy with infrared dermal thermometry. *J Rehab Res Devel* 1997;34:317–21.
23. Wang JC, Le AW, Tsukuda RK. A new technique for Charcot's foot reconstruction. *J Am Podiatr Med Assoc* 2002;92:429–36.
24. Simon SR, Tejwani SG, Wilson DL, Santner TJ, Denniston NL. Arthrodesis as an early alternative to nonoperative management of Charcot arthropathy of the diabetic foot. *J Bone Joint Surg Am* 2000;82A:939–50.
25. Fishco WD. Surgically induced Charcot's foot. *J Am Podiatr Med Assoc* 2001;91:388–93.
- 
- Correspondence:** Dr. R.A. Slater, Diabetes Unit, Sherman Outpatient Building, Assaf Harofeh Medical Center, Zerifin 70300, Israel.  
Phone: (972-8) 977-9640  
Fax: (972-8) 979-0545  
email: slater@netvision.net.il