

## Cough Syncope with Herpetic Tracheobronchitis

Jamal Awad MD and Ofer Schiller MD

Department of Internal Medicine F, Western Galilee Hospital, Nahariya, Israel

**Key words:** cough, syncope, herpes simplex, tracheobronchitis, acyclovir

*IMAJ 2001;3:284–285*

Although a rare condition, cough syncope is a frequent cause of hospitalization in internal medicine departments. The etiology is usually a vasovagal reflex. We present an unusual case of cough syncope due to viral infection.

### Patient Description

A 40 year old army general was admitted to the neurology ward for evaluation of syncope, which had occurred three times in the preceding month. He had a history of chronic bronchitis caused by smoking, and in the preceding month the cough had worsened significantly. He had no fever, chills, sweats or other symptoms to suggest an infection. The syncopal episodes occurred after prolonged episodes of cough. Because of his occupation, he underwent an exhaustive evaluation for syncope, which included brain computed tomography and magnetic resonance imaging scans, as well as electroencephalography, echo Doppler of the carotid arteries, electrocardiography, Doppler echocardiogram, 24 hour Holter monitoring, late potentials and a tilt test. All were within normal limits.

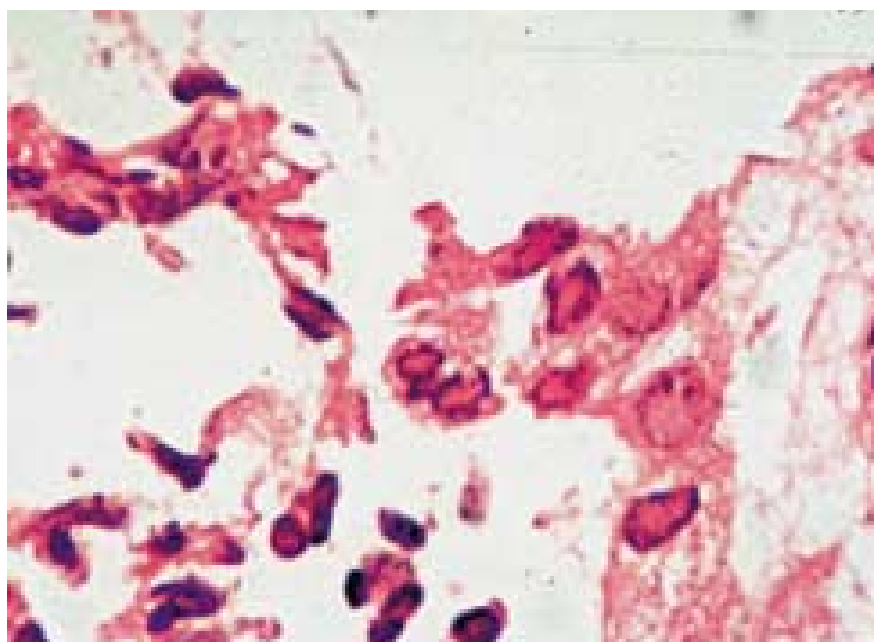
Evaluation of cough included normal chest X-ray, spirometry revealing reversible small airway disease, and sinus CT scan revealing pansinusitis. Further workup included a Mantoux test as well as allergy skin tests and a complete serology, all of which were negative. He received oral antibiotics, and inhaled bronchodilator and glucocorticosteroid

therapy both for sinusitis and for exacerbation of chronic bronchitis. CT scans of the neck and chest, barium swallow and laryngoscopy were normal.

Nasopharyngoscopy revealed an area of hyperplastic mucosa of the septum, which was shown on biopsy to be an inflammatory process with typical eosinophilic intranuclear inclusions in epithelial cells [Figure] compatible with herpes simplex virus. Immunohistochemical staining was positive for HSV. Flexible bronchoscopy showed diffuse bronchial mucosal irritation, and bron-

chial washings and swabs were negative for acid-fast organisms. Viral cultures were positive for HSV.

After 2 weeks of the above treatment in hospital with no amelioration of the cough, he developed a fever of 38–39°C that persisted for 3 days. Because of the positive nasal biopsy for HSV and findings compatible with HSV tracheobronchitis on bronchoscopy, intravenous acyclovir at a dose of 750 mg three times daily was begun, which resulted in the disappearance of fever and cough within 2 days. Acyclovir was



Epithelial cells from nasal mucosa showing diagnostic eosinophilic intranuclear viral inclusions (hemtoxylin and eosin. x 600).

HSV = herpes simplex virus

discontinued on day 6 because of an increased serum creatinine concentration that normalized within days. He was discharged symptom free, and remained so after 1 year of follow-up.

## Comment

Cough syncope is a rare condition that follows cough paroxysms. During prolonged coughing, intrathoracic and intraabdominal pressures are transmitted via the great veins to the intracranial compartment, causing transient elevated intracranial pressure and secondary reduction of cerebral perfusion pressure. At a critical low cerebral blood flow, syncope ensues [1].

The diagnosis of cough syncope is usually based on the patient's history. It occurs most commonly in middle-aged male smokers, but has also been described in children with asthma, in patients with whooping cough, in association with idiopathic hypertrophic subaortic stenosis, and in patients treated with angiotensin-converting enzyme inhibitors. This is the first reported case of cough syncope caused by herpetic tracheobronchitis.

Herpetic tracheobronchitis is uncommon,

and is usually seen in immunocompromised patients or those who have sustained trauma to their tracheal epithelium [2,3]. This entity is increasingly seen in apparently healthy individuals [3,4]. Clinical manifestations range from asymptomatic infection to persistent unremittent bronchospasm or severe tracheobronchitis with widespread mucosal ulceration. Diagnostic criteria are not clearly defined, and the diagnosis is usually made on the basis of viral cultures or specific staining methodologies of biopsy specimens, clinical status of the patient, and a suggestive appearance on bronchoscopy [2–6]. Acyclovir therapy results in significant clinical improvement.

Some authorities believe that herpetic tracheobronchitis is significantly underdiagnosed [2,4]. This entity should be suspected in any patient presenting with prolonged cough refractory to the usual therapy, as well as in patients with tracheobronchitis who fail to show improvement with antibacterial therapy. In conclusion, we recommend that bronchoscopy be performed in every patient with prolonged cough not responding to usual therapy.

## References

1. Mattle HP, Nirkko AC, Baumgartner RW, Sturzenegger M. Transient cerebral circulatory arrest coincides with fainting in cough syncope. *Neurology* 1995;45:498–501.
2. Legge RH, Thompson AB, Linder J, Woods GL, Robbins RA, Moulton AL, Rennard SI. Acyclovir-responsive herpetic tracheobronchitis. *Am J Med* 1988;85:561–63.
3. Schuller D. Lower respiratory reactivation of herpes simplex virus: comparison of immunocompromised and immunocompetent hosts. *Chest* 1994;106(Suppl July) 3–7S.
4. Sherry MK, Klainer AS, Wolff M, Gerhard H. Herpetic tracheobronchitis. *Ann Intern Med* 1988;109:229–33.
5. Bedrossian CW, DeArce EA, Bedrossian UK, Kelly LV. Herpetic tracheobronchitis detected at bronchoscopy: cytologic diagnosis by the immunoperoxidase method. *Diagn Cytopathol* 1985;1:292–9.
6. Schuller D, Spessert C, Fraser VJ, Goodenberger DM. Herpes simplex virus respiratory tract secretions: epidemiology, clinical characteristics, and outcome in immunocompromised and nonimmunocompromised hosts. *Am J Med* 1993;94:29–33.

---

**Correspondence:** Dr J. Awad, Senior Physician, Dept. of Internal Medicine F, Western Galilee Hospital, Nahariya 22100, Israel. Phone: (972-4) 985-0520, Fax: (972-4) 985-0611, email: jamal\_awad@hotmail.co.il